

Chiari EDS Program

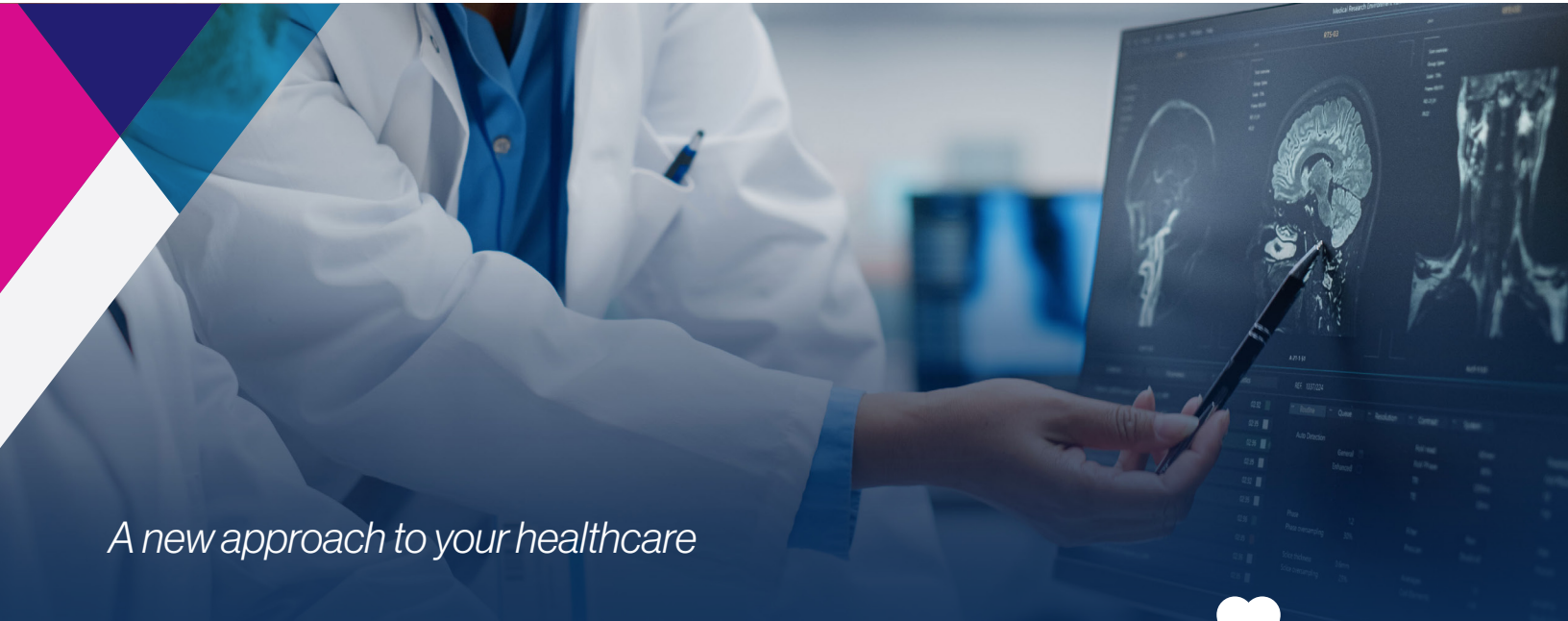NEWSLETTER | SPRING 2023

CONTENTS

Chiari EDS Program News
PAGE 1

Publications
PAGE 4

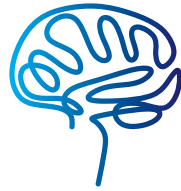Open Projects
PAGE 2-4



A new approach to your healthcare

News

The latest news from the Chiari EDS Program




On August 28, 2021, The Chiari Neurosurgical Center adopted a new name: **Chiari EDS Center**, with the opening of new clinical offices at 242 Merrick Road, Rockville Centre, NY in late January 2022 – led by Dr. Paolo A. Bolognese, M.D. (Surgical Director) and Dr. Ilene S. Ruhoy, M.D., Ph.D. (Administrative Medical Director). Reflecting the renewed focus of the group, all in close cooperation and with the full support of Mount Sinai South Nassau, our multidisciplinary structure emphasizes the comprehensive treatment, prevention, and clinical research of Chiari, Ehlers-Danlos syndrome, and related disorders, including:

- Mast Cell Activation Disorder (MCAD)
- Chiari I Malformation
- Dysautonomia
- Myalgic Encephalomyelitis/Chronic Fatigue Syndrome
- Postural Orthostatic Tachycardia Syndrome
- Styloid Hypertrophy and Eagle Syndrome
- Post-Treatment Lyme Disease Syndrome
- Immune Dysfunction
- Syringomyelia

- Craniocervical Instability
- Idiopathic Intracranial Hypertension
- Intracranial Hypotension
- Tethered Cord
- CSF Leaks
- Hydrocephalus
- Small Fiber Neuropathy
- Cervical Instability
- Cervical Disc Herniations
- Lumbar Instability and Dislocations
- Dysmotility
- Long Covid

Of note, we are increasingly seeing patients in the Chiari/EDS/MCAD spectrum struggling with debilitating long term post-viral issues in the wake of the global SARS-CoV-2 pandemic — a condition now widely referred to as Long Covid. Recognizing its urgency, we are actively expanding our clinical practices towards including a detailed protocol to monitor and treat Long Covid, complete with obtaining tissue samples for genetic analysis of patients. Funding acquisition for this project is underway.



MAKE A DONATION
Visit www.southnassau.org/donate and select Chiari EDS Program from the "allocate my gift" drop down menu.

We're growing! Dr. John Biggins, Ph.D., who has over 25 years of experience in biomedical research, joined our team as our new Research Director. He comes to us after being a founding team member at LifeMine Therapeutics, a biotech leveraging genomics technology towards developing next-generation drugs targeting the primary cellular drivers of cancer-, immunology-, and neuroscience-related diseases. Dr. Biggins was previously on the faculty of Hofstra University and has past affiliations with Rockefeller University, Weill Cornell Medical College, Memorial Sloan-Kettering Cancer Center, University of Wisconsin-Madison, and University of Delaware.

In November 2022, we welcomed the addition of Neuro-interventional Radiologist, Dr. Travis Caton, M.D. Dr. Caton is a graduate of Columbia University College of Physicians and Surgeons and has completed advanced training in diagnostic neuroradiology from University of California-San Francisco. Dr. Caton provides critical expertise in multiple areas of intra- and

News

Continued from page 1 >

extra-cranial circulatory and cerebrospinal disorders, bringing experience for the seamless internalization of multiple diagnostic tools for the Chiari EDS Center clinical pathway.

Dr. Ilene Ruhoy has been made Chair of the Neurology Working Group of the Ehlers-Danlos Society.

We're getting noticed! Our recent progress in tethered spinal cord surgeries have caught the attention of prominent surgeons in the field, who have invited our Surgical Team to the 2023 annual Complex Spine surgical symposium.

Outreach. In 2022, members of the Chiari EDS Center were invited to give lectures presenting clinical data at the American Syringomyelia and Chiari Alliance Project (ASAP) Conference (July 2022, Chicago) and 2nd Chiari and Syringomyelia Conference (Dec 2022, Beijing).

In the news. There has been increased exposure of personal experiences of people living with EDS in the press and our need to increase public awareness for proper diagnosis and management. Sarah Lazarus, correspondent for CNN, recently profiled hypermobile EDS and her teenage daughter's experiences with it, providing much-needed exposure and advocacy to the underdiagnosis of patients within the EDS spectrum (Weblink: bit.ly/CNN-EDS). Additionally, a report in The Sun profiles the common years-long misdiagnoses of a woman suffering numerous debilitating immune and autonomic symptoms, until finally pinpointing her condition to be EDS and related mast cell dysfunction (Weblink: bit.ly/TheSunEDS).

The Mount Sinai South Nassau Chiari EDS Center offers the highest available diagnostic and state-of-the-art treatment options for patients with Chiari/EDS/MCAD-related issues – organized towards integrating all aspects of pre-, post-, and non-surgical outcomes – for a reliable new standard of patient care.

Notably, our consortium is currently the only medical organization in the United States specifically designed to address the pressing and unmet needs of the diverse patient population within the entire Chiari/EDS/MCAD spectrum.

It is through the support from people like you that will see to the continued success and expansion of our shared vision of first-rate research and treatment for the Chiari/EDS spectrum [For further information, please contact Dr. John Biggins, Chiari EDS Center Research Director; Email: john.biggins@snych.org]

Open Projects

A. Surgical management of craniocervical instability in patients with connective tissue disorder

Primary Investigator: Dr. Bolognese.
IRB approved.



This is the first prospective observational study of its kind in the field of craniocervical instability and connective tissue disorder, based on the criteria developed in our surgical practice for years, serving 55

enrolled patients to date. Downstream analysis includes partnership with **Stanford Genome Technology Center** and the **J. Craig Venter Institute** for advanced genetics analyses and the **National Primate Research Center at Tulane University** for pathology and tissue analysis. In addition to patients with confirmed craniocervical instability, the population included various comorbidities such as Chiari I malformation, Ehlers-Danlos syndrome, acquired tethered cord syndrome, mast cell activation disease, myalgic encephalomyelitis-chronic fatigue syndrome, and post-treatment Lyme disease syndrome. The observation that a subset of patients had post-treatment Lyme disease syndrome has led to a collaboration with Tulane University. The etiology of these symptoms is unknown; however, several mechanisms including microbial persistence, immune dysregulation, or altered neural networks have been hypothesized as causative or contributing factors.

B. Styloid Induced Neuropathy of the Glossopharyngeal Nerve

Primary Investigator: Dr. Bolognese.
IRB approved.

The purpose of this study is to learn how styloid-induced neuropathy contributes to the pathology of patients with Chiari I malformation, Ehlers-Danlos syndrome, and related disorders. We have recently identified several patients affected by both Chiari malformation and styloid hypertrophy, in whom we detected an unprecedented syndromic clinical presentation, which is different from and more complex than the known variants of Eagle syndrome. This new syndrome clinically appears to be linked to a stretch neuropathy of the glossopharyngeal nerve, where it exits the skull base and wraps around the styloid process. The clinical presentation stems from the involvement of the different segments and branches of the glossopharyngeal nerve and includes altered

tongue sensation, altered salivation, cardiac irregularities, swallowing difficulty, hearing difficulty, and localized pain – overlapping with the characteristics of glossopharyngeal neuralgia and Eagle syndrome. Patients with severely debilitating symptoms that were unresponsive to conservative management were selected for surgical treatment, which is now the current standard of care. The observed co-morbidities in patients include Ehlers-Danlos syndrome (92%), Chiari malformation Type I (85%), tethered spinal cord (36%), and mast cell activation disease (41%) – thus providing empirical data supporting the hypothesis that connects styloid hypertrophy within the Chiari/EDS spectrum. A five-year follow-up is underway with post-operative questionnaires.

C. Investigations into diagnosis and treatment of small fiber polyneuropathy

C1. Exploration of infectious, immune, and genetic contributors to small fiber polyneuropathy

Primary Investigator: Dr. Ruhoy.
IRB approved.



We seek to better identify and understand biological factors that contribute to the development of small fiber polyneuropathy (SFPN) in patients with disorders as EDS, myalgic encephalomyelitis/

chronic fatigue syndrome, post-treatment Lyme disease syndrome, fibromyalgia, and the emerging prevalence of post-acute sequelae of COVID-19 (PASC, commonly referred to as long haul- or Long Covid). As routine electrodiagnostic study does not detect SFPN, tissue biopsies are required for diagnostic confirmation. Punch biopsy tissue samples are assessed for epidermal nerve fiber density and/or sweat gland nerve fiber density, and if the density of epidermal nerve fibers is decreased, as compared to established normative data, a diagnosis of SFPN is supported.

Our goal is to create a tissue bank of research-dedicated biopsies of consenting SFPN patients and control subjects for analysis – concentrating on genetic, immune, or infectious issues or abnormalities among the patient populations. We expect deeper analyses of the tissue biopsy samples will lead to better treatment options for patients with SFPN. A primary study investigating the disease processes, examining both clinical

Continued on page 3 >

Open Projects



Continued from page 2 >

and genetic aspects of SFPN, is underway. Material transfer agreements between Mount Sinai South Nassau and the **J. Craig Venter Institute** for genetics analyses is in progress. Additionally, a collaborative grant application to the Steven and Alexandra Cohen Foundation has been submitted.

C2. Exploration of the contribution of aberrant synuclein expression in small fiber polyneuropathy pathology

Primary Investigator: Dr. Ruhoy.
IRB approved.

The cellular accumulation of a phosphorylated form of the protein alpha-synuclein (aka. "P-syn") results in an aberrant misfolded version of synuclein that has been shown to be intrinsically linked to neuroinflammatory diseases. Increasing evidence shows the potential of P-syn as a putative factor in autonomic dysfunction, including a likely association in SFPN disease progression. This data, though promising, lacks a thorough interrogation with a robust patient cohort. Taking advantage of our SFPN biopsy protocol, we will run a parallel investigative study for quantifying the presence of P-syn in the cutaneous epidermal nerve tissue of our patient population. Our goal here is to quantify the relevance of aberrant synuclein expression in SFPN, thereby providing a comprehensive and easy tool for the diagnosis of neuropathic conditions with underlying orthostatic intolerance.

D. Autologous Adipose-Derived Stromal Vascular Fraction to Repair Degenerative Neurological Conditions Refractory to Conventional Treatments

Primary Investigator: Dr. Ruhoy.
IRB approval, in submission.

Adult adipose derived stem cells (ADSCs) are cells that are highly similar to adult mesenchymal stem cells (MSCs). There is significant data demonstrating the benefits that MSC treatment has on inflammatory and degenerative conditions. Whereas MSCs are derived from bone marrow, ADSCs are derived from the stromal vascular fraction (SVF) of human adipose (fat) tissue, which is considerably easier to extract from patients, and compared to MSCs, data supporting ADSC-based treatment is in its infancy. Our intent is to demonstrate the efficacy of using SVF-derived ADSCs for the treatment of degenerative neurological conditions based upon patient evaluation and objective findings.

This protocol investigates the use of autologous mesenchymal stem cells towards treating inflammatory and ischemic processes refractory to conventional treatments and its safety. Relevant medical conditions include myalgic encephalomyelitis, connective tissue disorder, post-viral encephalitis, and autoimmune encephalitis. The primary outcome should demonstrate that administration of autologous SVF, as produced by this protocol, produces an efficacious response to many of the neurological conditions treated. Secondly, we intend to demonstrate a reasonable level of safety and ease inherent in our protocol towards establishing SVF extraction as a viable diagnostic tool.

E. Retrospective chart review of the Chiari Neurosurgical Center

Primary Investigator: Dr. Bolognese.
IRB approved.

E1. Safety analysis and complications of condylar screws in a single-surgeon series of 250 occipitocervical fusions

A retrospective safety and complication-based analysis of occipitocervical fusion via condylar screws fixation (i.e., bone implantation) was performed. Methodical dissection of anatomical landmarks, intraoperative imaging, and neurophysiologic monitoring allowed the safe execution of the largest series of condylar screws reported to date. In the timespan of 2012-2018, a total of 250 patients underwent occipitocervical fusions using 500 condylar screws, from which no condylar screw pullouts or vertebral artery migration were observed in this series. Additionally, the sacrifice of condylar veins during the dissection at C0-1 did not cause any venous stroke. Condylar hypertrophy in a subset of patients (roughly one-third) did not prevent the insertion of condylar screws. This surgical series suggests that the use of condylar screws fixation is a relatively safe and reliable option in both adult and pediatric patients. Separate contributions will follow in the future to provide details about the long-term clinical outcome of this series.

E2. Electromyographic assessment of condylar screw placement during occipitocervical fusion

This is a retrospective study of a series of occipitocervical fusion procedures with condylar screw fixation in which the authors investigated the utility of electromyography (EMG, free-running and triggered) as a reliable tool in assessing the positioning of condylar screws.

Intraoperative free-running EMG and triggered EMG were able to correlate alerts with condylar screw placement accurately for the 197 patients with craniocervical instability who were treated within 2014-2017. A triggered EMG threshold of 2.7 mA was found to be a minimum acceptable threshold. A combination criterion of free-running EMG and triggered EMG alerts was found to enable accurate assessment of condylar screw positioning and placement.

E3. Establish the role of Invasive Cervical Traction (ICT) as an important diagnostic tool for craniocervical instability in patients with connective tissue disorder.

To guide a selection of reliable candidates for fusion/stabilization of craniocervical junction, we analyzed a cohort of over 200 consecutive patients who underwent ICT testing a single center from 2015-2021. Of note, there was a 7-to-1 preponderance of females-to-male in the patient pool. Roughly half of patients had craniocervical fusion based on ICT with ~95% of this subset diagnosed with Ehlers-Danlos syndrome. ICT of patients resulted in significant improvement in morphometric measurements of the craniocervical junction, as well as notable improvement in presenting symptoms as blurred vision (71%), swallowing difficulties (67%), headache (64%), breathing difficulties (55%), brain fog (52%), neck pain (49%), and fatigue (41%) Results of this protocol are currently submitted for publication.

F. Exploration of Nevisense for impedance and tissue oxygenation in mast cell dysregulation

Primary Investigator: Dr. Ruhoy.
IRB approval, in submission.

Connective tissue is integral to the structure of blood and lymphatic vessels, and therefore, genetic changes may affect vessel compliance resulting in an increase in permeability especially when under increased pressure. As identified via electronic microscopy, the "soft, velvety skin", a marker of a hypermobile Ehlers Danlos hypermobile spectrum disorder (HEDS/HSD) likely reflects abnormal collagen fibers and abnormal glycocalyx barrier function. The abnormal glycocalyx barrier function, from the ability of dermal fibers to separate, may impact capillary diffusion, lead to increased hydrostatic pressure, and predispose the dermis to non-serological inflammation.

Electrical impedance spectroscopy (EIS) has become a useful tool in detecting skin barrier dysfunction in a variety of conditions and recently

Continued on page 4 >

Open Projects

Continued from page 3 >

has been used in establishing biomarkers for physiological differences within various dermatological diseases. Using the Nevisense device – an EIS monitor capable of detecting alterations in the electric conductance of skin tissue in a benign, normal clinical setting – we have established a non-invasive tool for improved diagnostics in the monitoring of disorders along the EDS spectrum, correlating the dysfunction of the glycocalyx barrier with tissue perfusion index. As our center sees hundreds of patients per year, we have the capability to assess the extent of skin barrier dysfunction in our patient population to foster the development of this EIS protocol as a standard clinical tool.

G. Exploration of Therapeutic Benefits of Plasmapheresis in Mast Cell Activation Disease

Primary Investigator: Dr. Ruhoy.
IRB approval, in submission.

Plasmapheresis or therapeutic plasma exchange (TPE) a therapeutic process where patient plasma is separated from blood cells and removed to deplete the concentration of factors in patient blood contributing to autoimmune dysfunction

– factors like histamine and certain antibodies. Although clinical studies have shown the usefulness of TPE in alleviating symptoms related to mast cell activation disorder (MCAD), a thorough investigation into the effectiveness of TPE is lacking. We are initiating a comprehensive study to specifically address this blind-spot, by assessing the effectiveness of TPE treatment in a focused EDS/MCAD patient population – monitoring patient progress, pre- and post-TPE treatment, to identify potential disease-associated molecular markers. Through a two-pronged analysis of both (A) known MCAD-related biomarkers and (B) comprehensive metabolomics data of collected plasma, information derived from this study is expected to afford significant advances in both treatment and diagnosis of MCAD-related autoimmune dysfunction.

I. Development of a Screening Tool for Identifying Craniocervical Instability in the Primary Care Setting

Primary Investigator: Dr. Bolognese.
IRB approval, in submission.

To date, there is no reliable screening tool in the primary care setting of patients suffering from

craniocervical instability (CCI). Leveraging our internal data of hundreds of CCI patients seen by Chiari EDS Center and its past incarnations, we are developing a new self-assessment survey tool for reliable CCI diagnosis. Using screening questions that focus on only on basic predictive factors, this survey is intended to be intentionally brief to increase ease of both (A) patients to respond reliably and (B) adoption by other clinicians to use in their diagnoses. Coupled with the proven power of our Invasive Cervical Traction methods, we anticipate this screener to be a superior method to effectively gauge CCI patient status.

Publishers Marketplace Deal Report

Non-fiction: Health/Medicine
February 21, 2023

Our Chiari EDS Center Administrative Medical Director, **Ilene Ruhoy MD PhD**, will soon be publishing *INVISIBLE NO MORE* (St. Martin's Essentials Press), an exploration in to the epidemic of post-viral illnesses, including Long Covid. Woven as a critique of the medical system, this tome details Dr. Ruhoy's journey as a brain tumor patient and explores post-viral mitigation strategies and prevention.



Chiari EDS Program

NEWSLETTER | SPRING 2023

www.southnassau.org/sn/chiari-eds

Clinical Team

Paolo A. Bolognese, MD
Surgical Director
Ilene S. Ruhoy, MD, PhD
Administrative Medical Director,
Neurologist
Michael Travis Caton, MD
Neuroradiologist
George Xipoleas, MD, FACS
Plastic Surgeon
Gad Klein, PhD
Neuropsychologist
Anne Maitland, MD, PhD
Allergist and Immunologist
Roger W. Kula, MD, FAAN
Former Medical Director
Stelios Koutsoumbelis, MD
Orthopedic Surgeon
Yelena Markovskaya, MD
Infectious Disease Specialist
John Pile-Spellman, MD, FACR
Neuro-Interventional Specialist
Prajay Kadkade, MD
ENT

Marat Avshalumov, PhD
Denmark Mugutso, MS, CNIM
Intra-Operative
Neurophysiological Monitoring
Mariam Sheikh, DO
Anesthesiologist
Philip Papadimas, PA
Jackie Amaru, PA
Miguel Gonzalez, PA
Physician Assistants
Cynthia Borquez, RN
Nursing

Research Team

John B. Biggins, PhD
Research Director
Navdeep Nayyar, MD, MBA
Junior Research Director
Jeff Wood, MA
Data Collection and Screening
Coordinator

Administrative Team

Catherine Soto, BSN, RN, CCRN
Yansi Interiano, MPA

Publications

- 1) Ciaramitaro P, Massimi L, Bertuccio A, Solari A, Farinotti M, Peretta P, Saletti V, Chiapparini L, Barbanera A, Garbossa D, **Bolognese P**, Brodbelt A, Celada C, Cocito D, Curone M, Devigili G, Erbetta A, Ferraris M, Furlanetto M, Gilanton M, Jallo G, Karadjova M, Klekamp J, Massaro F, Morar S, Parker F, Perrini P, Poca MA, Sahuquillo J, Stoodley M, Talamonti G, Triulzi F, Valentini MC, Visocchi M, Valentini L; International Experts Jury of the Chiari Syringomyelia Consensus Conference, Milan, November 11-13, 2019. Diagnosis and treatment of Chiari malformation and syringomyelia in adults: international consensus document. *Neuro Sci*. 2022 Feb;43(2):1327-1342. doi: 10.1007/s10072-021-05347-3. Epub 2021 Jun 15. Erratum in: *Neuro Sci*. 2021 Nov 17; PMID: 34129128.
- 2) Tam SKP, **Bolognese PA**, Kula RW, Brodbelt A, Foroughi M, Avshalumov M, Mugutso D, **Ruhoy I**. Safety analysis and complications of condylar screws in a single-surgeon series of 250 occipitocervical fusions. *Acta Neurochir (Wien)*. 2021 Nov 25. doi: 10.1007/s00701-021-05039-z. Epub ahead of print. PMID: 34820740.
- 3) Mugutso D, Warnecke C, **Bolognese P**, Avshalumov MV. Electromyographic assessment of condylar screw placement during occipitocervical fusion. *J Neurosurg Spine*. 2021 Sep 24;14(10). doi: 10.3171/2021.3.SPINE201793. Epub ahead of print. PMID: 34560655.
- 4) Nishikawa M, **Bolognese PA**, Kula RW, Ikuno H, Ohata K. Pathogenesis and Classification of Chiari Malformation Type I Based on the Mechanism of Potosis of the Brain Stem and Cerebellum: A Morphometric Study of the Posterior Cranial Fossa and Craniovertebral Junction. *J Neurol Surg B Skull Base*. 2021 Jun;82(3):277-284. doi: 10.1055/s-0039-1697977. Epub 2019 Sep 30. PMID: 34026403; PMCID: PMC8133809.
- 5) Nishikawa M, **Bolognese PA**, Kula RW, Ikuno H, Takami T, Ohata K. Surgical Management of Chiari Malformations: Preliminary Results of Surgery According to the Mechanisms of Potosis of the Brain Stem and Cerebellum. *J Neurol Surg B Skull Base*. 2021 Apr;82(2):264-272. doi: 10.1055/s-0039-1697977. Epub 2019 Sep 30. PMID: 33816049; PMCID: PMC8009696.
- 6) Tam SKP, Brodbelt A, **Bolognese PA**, Foroughi M. Posterior fossa decompression with duraplasty in Chiari malformation type I: a systematic review and meta-analysis. *Acta Neurochir (Wien)*. 2021 Jan;163(1):229-238. doi: 10.1007/s00701-020-04403-9. Epub 2020 Jun 23. PMID: 32577895.
- 7) **Bolognese PA**, Brodbelt A, Bloom AB, Kula RW. Professional Profiles, Technical Preferences, Surgical Opinions, and Management of Clinical Scenarios from a Panel of 63 International Experts in the Field of Chiari I Malformation. *World Neurosurg*. 2020 Aug;140:e14-e22. doi: 10.1016/j.wneu.2020.03.119. Epub 2020 Apr 3. PMID: 32251822.
- 8) Bateman L, Bested AC, Bonilla HF, Chheda BV, Chu L, Curtin JM, Dempsey TT, Dimmock ME, Dowell TG, Felsenstein D, Kaufman DL, Klimas NG, Komaroff AL, Lapp CW, Levine SM, Montoya JG, Natelson BH, Peterson DL, Podell RN, Rey IR, **Ruhoy IS**, Vera-Nunez MA, Yellman BP. Myalgic Encephalomyelitis/Chronic Fatigue Syndrome: Essentials of Diagnosis and Management. *Mayo Clin Proc*. 2021 Nov;96(11):2861-2878. doi: 10.1016/j.mayocp.2021.07.004. Epub 2021 Aug 25. PMID: 34454716.
- 9) Weiler CR, Austen KF, Akin C, Barkoff MS, Bernstein JA, Bonadonna P, Butterfield JH, Carter M, Fox CC, **Maitland A**, Pongdee T, Mustafa SS, Ravi A, Tobin MC, Vliagoftis H, Schwartz LB. AAAAAA Mast Cell Disorders Committee Work Group Report: Mast cell activation syndrome (MCAS) diagnosis and management. *J Allergy Clin Immunol* 2019 Oct;144(4):883-896. DOI: 10.1016/j.jaci.2019.08.023. Epub 2019 Aug 30. PMID: 31476322.
- 10) Brock I, Prendergast W, **Maitland A**. Mast cell activation disease and immunoglobulin deficiency in patients with hypermobile Ehlers-Danlos syndrome/hypermobility spectrum disorder. *Am J Med Genet C Semin Med Genet*. 2021 Dec;187(4):473-481. doi: 10.1002/ajmg.c.31940. Epub 2021 Nov 7. PMID: 34747107.
- 11) Gotlib J, George T, Carter MC, Austen KF, Bochner B, Dwyer DF, Lyons JI, Hamilton MJ, Butterfield J, Bonadonna P, Weiler C, Galli SJ, Schwartz LB, Elberink HO, **Maitland A**, Theoharides T, Ustun C, Horny HP, Orfao A, Deininger M, Radia D, Jawhar M, Klein-Nelms H, Metcalfe DD, Arock M, Sperr WR, Valent P, Castells M, Akin C. Proceedings from the Inaugural American Initiative in Mast Cell Diseases (AIM) Investigator Conference. *J Allergy Clin Immunol*. 2021 Jun;147(6):2043-2052. doi: 10.1016/j.jaci.2021.03.008. Epub 2021 Mar 11. PMID: 33745886.
- 12) Tam SKP, **Bolognese PA**, Kula RW, Brodbelt A, Foroughi M, Avshalumov M, Mugutso D, Ruhoy I. Safety analysis and complications of condylar screws in a single-surgeon series of 250 occipitocervical fusions. *Acta Neurochir (Wien)*. 2022 Mar;164(3):303-311. doi: 10.1007/s00701-021-05039-z. Epub 2021 Nov 25. DOI: 10.1007/s00701-021-05039-z. PMID: 34820740
- 13) Biggins JB, Nishikawa M, **Ruhoy IS**, **Maitland A**, Kula RW, Brodbelt A, Foroughi M, Nayyar N, Rohana K, Wood J, **Bolognese PA**. Invasive Cervical Traction as a Diagnostic Tool in Craniocervical Instability Secondary to Ehlers Danlos Syndrome and other Connective Tissue Disorders: Analysis of a 217 Patient Case Series. Manuscript submitted.